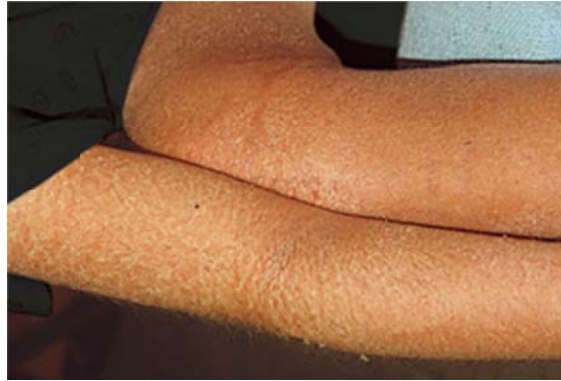


CASE 28-2

A 20-year-old woman presents with a 3-week history of widespread erythema and desquamation of the skin. The skin is not tender, but is pruritic and warm. An exfoliative erythroderma is the working diagnosis.



The best management of this exfoliative erythroderma during early admission includes:

- (A) High dose systemic steroids on admission
- (B) Broad-spectrum antibiotics on admission
- (C) Assessment and management of fluid status, temperature control, surveillance/culture for secondary infection and wet wraps
- (D) Skin biopsy with all management to follow
- (E) Oral methotrexate on admission

The correct answer is (C), assessment and management of fluid status, temperature control, surveillance/culture for secondary infection and wet wraps.

The management of exfoliative erythroderma in the hospital requires that initially the patient's fluid status, temperature control, and the possibility of secondary infection be assessed as management of these aspects of the disease is critical. Regarding the etiology of the erythroderma, the history can often give valuable information: the patient may have had pre-existing skin disease that has evolved (psoriasis or atopic dermatitis), or may have been exposed to a new drug. The patient may have an underlying lymphoma (Sezary syndrome). Systemic therapy should be directed at the most likely underlying cause. There is no role for antibiotics empirically; prednisone or methotrexate may be useful if underlying responsive disease is suspected but are generally not ordered until some diagnostic tests are complete. Skin biopsies are routinely performed but do not always distinguish the underlying etiology and initial treatment can still begin.